

The Natural Evolution of Facial Surgical Scars: A Retrospective Study of Physician-Assessed Scars Using the Patient and Observer Scar Assessment Scale Over Two Time Points

Kimberly Shao, MD,¹ Lynne Taylor, PhD,² Christopher J. Miller, MD,³ Jeremy R. Etzkorn, MD,³
Thuzar M. Shin, MD, PhD,³ H. William Higgins, II, MD,³ Cerrene N. Giordano, MD,³ and Joseph F. Sobanko, MD^{3,*}

Abstract

Background: The natural evolution of facial scars has not been well described. Identifying factors that correlate with optimal scar healing may help patients and physicians during the perioperative period.

Methods: A retrospective study of 108 facial skin cancer patient scars was performed. The Patient and Observer Scar Assessment Scale (POSAS) was used to grade scars at two time points (1 week and 3 months postoperatively). Paired two-tailed *t*-tests identified differences in scar ratings between the time points. Analysis of variance (ANOVA) explored whether POSAS scores differed by anatomic site or reconstruction type. Receiver operating characteristic analysis was performed to identify if 1-week scar appearance correlated with scar appearance at 3 months.

Results: Between 1 week and 3 months the total POSAS score improved by 36.3% and overall opinion of the scar improved by 38.6% ($p < 0.001$). Facial cosmetic units differed in their 1-week and 3-month scores and all anatomic sites demonstrated significant improvement between time points. Differential scoring occurred among reconstruction types. Scar appearance at 1 week was able to predict overall scar appearance at the 3-month visit (area under the curve = 0.7732).

Conclusions: Early scar appearance predicts later scar appearance, and scars will improve by nearly 40% 3 months after surgery. These data can be used to assist with perioperative counseling and expectation management.

Introduction

Skin cancer patients' expectations for scarring differ across diverse social, emotional, and cosmetic domains.¹ Concerns about facial scars are elevated before skin cancer surgery² and peak 1–2 weeks after surgery.³ By 3 months after surgery, patients are often more satisfied with their scars.³ Making scars less noticeable as quickly as possible may relieve patient anxiety.⁴

Setting realistic expectations affects patient perceptions of outcomes.^{5,6} Patients are more likely to be satisfied with their care when preoperative expectations are

achieved.^{7–9} Conversely, patients are more likely to litigate and be dissatisfied with care when surgery does not meet their expectations.¹⁰

One strategy to set realistic expectations is to address common patient misconceptions. For example, since 80% of Mohs micrographic surgery (MMS) patients expect scars to be less than half of their actual final length,¹¹ surgeons can realign expectations by emphasizing the anticipated length of scar before surgery. Another strategy to set expectations is to explain how the appearance of the scar will change after surgery. However, few studies

¹Department of Dermatology, University of Connecticut, Farmington, Connecticut, USA.

²Center for Clinical Epidemiology and Biostatistics, University of Pennsylvania, Philadelphia, Pennsylvania, USA.

³Department of Dermatology, University of Pennsylvania Health System, Philadelphia, Pennsylvania, USA.

*Address correspondence to: Joseph F. Sobanko, MD, Perelman Center for Advanced Medicine, 3400 Civic Center Boulevard 1-330S, Philadelphia, PA 19104, USA, Email: joseph.sobanko@pennmedicine.upenn.edu

KEY POINTS

- **Question:** Is there a way to quantify facial scar improvement and identify if scar appearance at 1 week predicts scar appearance at 3 months, the time period where patient postoperative anxiety is highest?
- **Findings:** Patients can be reassured that facial scars improve nearly 40% between 1 week and 3 months after surgery. Scars that begin healing well 1 week after surgery are more likely to heal with the highest aesthetic results at 3 months.
- **Meaning:** These findings may improve the informed consent process before surgery, allow surgeons to set realistic expectations for scar healing, and assist with reconstructive decision-making.

have rigorously assessed the maturation of facial scars after surgery,¹² so surgeons have limited objective data to counsel patients about scar evolution.

This study compared scar appearance 1 week and 3 months after MMS and reconstruction of facial skin cancers. The primary objectives of this study were to (1) quantify the improvement of scars between the 1-week and 3-month office visits, and (2) determine whether 1-week scar appearance could predict the scar appearance at 3 months. These data will help surgeons to counsel patients at the peak of anxiety 1–2 weeks after surgery and set realistic expectations about 3-month scar appearance.

Methods

Study design

We conducted a retrospective study of scar appearance in consecutive skin cancer patients at a single outpatient surgical facility. Protocol and ethics were approved by the Institutional Review Board (IRB) of the University of Pennsylvania.

Participants

Adult patients treated for facial skin cancer with MMS at the Hospital of the University of Pennsylvania (Division of Dermatologic Surgery) from August 2015 to February 2016 were eligible. Patients were excluded if they did not have clinical photographs from their follow-up visits, if wounds were reconstructed with multiple methods, or if scars were treated with a postoperative intervention (e.g., laser, scar revision).

Protocol

Patient charts were reviewed for demographics, skin cancer diagnosis and location, and method of reconstruction. Tumor locations were divided into five facial cosmetic units: periorbital, forehead/temple, cheek, nose, and perioral. Reconstructions were divided into four subgroups: linear repair, local flap (e.g., advance-

ment, transposition), staged interpolation flap (e.g., paramedian forehead flap) and skin graft (e.g., full- or split-thickness).

High-resolution photographs of the surgical scars were taken with a Canon Rebel T3i (Melville, NY) at 18 megapixels and stored in the patients' medical records (Mirror; Canfield Scientific, Inc. ©). The clinical photographs were taken at scheduled 1- to 2-week and 3-month postoperative visits using a standardized protocol that included a frontal view and a profile view. The 3-month photos for staged flap patients occurred 3 months after flap division. Photos of each patient were downloaded to a digital slideshow (PowerPoint; Microsoft ©) and randomized, using Excel's (Microsoft) random number generator. The photographs were cropped to allow each facial profile (frontal, oblique, and lateral) to fit in a 11.4 cm (width) × 12.7 cm (height) rectangle. Photos were cropped such that the entire forehead to chin was included. Open eyes were covered to minimize identifiable features and paired arrows were added to point toward the ends of each scar line (Fig. 1).

Measures

Randomized photos of the scars were graded by four clinicians with an adapted Patient and Observer Scar Assessment Scale v.2 (POSAS),^{13,14} a validated measure of postsurgical scar quality. The observer component of the POSAS consists of seven discrete items: vascularity, pigmentation, thickness, relief, surface area, pliability, and overall opinion. Pliability was omitted due to the inability to assess this characteristic through photographs.¹⁴ Definitions of the remaining items are shown as follows:

- **Vascularity:** the presence of vessels in scar tissue assessed by the amount of redness
- **Pigmentation:** brownish coloration of the scar by pigment (melanin)
- **Thickness or depth:** the average height of the scar, compared with surrounding normal skin
- **Relief:** the extent to which surface irregularities are present
- **Surface area:** the visible absolute area of the scar
- **Overall opinion:** general impression of the scar.

Each item was graded on a 1–10 scale, with 1 representing “normal skin” and 10 representing the “worst imaginable scar.” The “total score” sums each individual scar characteristic and ranges from 5 (best possible scar) to 50 (worst possible scar). “Overall opinion” about scar appearance was graded separately on a scale from 1 (best possible scar) to 10 (worst possible scar).

Four clinicians independently graded the scar for each slide using this adapted observer portion of the POSAS, and scores for the four clinicians were averaged for each item in the POSAS. Inter-rater reliability was calculated (Appendix Table A2). Each patient follow-up slide

to be evaluated (1 week or 3 months) had front and profile views for that particular time point so that 108 patients generated 216 slides. The slides were randomly ordered to mitigate clinician recency grading bias.

Surgical technique and wound care

All patient wounds were full thickness to the adipose layer, muscle, or periosteum, and no defects had bony deficits. Patients had their defect repaired by Mohs surgeons with >7 years of experience. Clinical judgment was used to decide which repair option would likely heal “the best” for the given defect and consistent surgical technique for undermining and suturing has been previously described.^{15,16} For all defects on the forehead, temple, cheeks, lip, chin, and some nasal defects, dermal sutures were placed with 3-0 or 4-0 monofilament polyglyconate. Dermal sutures for periocular skin and some nasal defects were placed with 5-0 monofilament poligle-caprone. Clinical circumstances and anatomic locations dictated whether 5-0 or 6-0 polypropylene or 5-0 or 6-0 fast-absorbing gut sutures were placed for cuticular sutures.

Postoperatively, all patients with linear repairs and flaps were instructed to keep their pressure dressing in place for 24 h. Skin grafts were bolstered in place for 1 week. Once the bandage was removed, the area was to be washed gently everyday with soap and water, and then a thin coat of Vaseline was applied to area and covered with nonadherent gauze and tape. After 1 week of light bandaging, patients were allowed to continue daily cleansing and Vaseline application without a bandage.

Statistical analysis

All data analyses were performed with STATA version 14 (StataCorp 2015). Descriptive statistics were calculated for the patients’ pertinent sociodemographic factors, the scar’s anatomic location, and the reconstruction type.

Differences in scar appearance at 1 week–3 months. Both paired parametric and nonparametric two-tailed tests (paired *t*-test and paired Wilcoxon signed-rank test) were used to identify differences between POSAS scores at 1 week versus 3 months postoperatively. A significant difference was determined by $p < 0.05$. Percent-age change was used to quantify improvement.

As an exploratory analysis, to investigate whether average POSAS scores differed by the scar’s anatomic location or by the reconstruction type at 1 week and 3 months ($p < 0.05$), parametric (one-way analysis of variance [ANOVA]) and nonparametric (Kruskal–Wallis) tests were used. Our sample size was not adequately powered for a post hoc analysis.

Ability of 1-week scar appearance to predict 3-month scar appearance. A receiver operating characteristic (ROC) curve analysis was used to evaluate if overall

opinion scores at 1 week could predict overall opinion scores at 3 months. We expressed this discriminative ability as the area under the curve (AUC), which is considered adequate if the AUC is ≥ 0.7 .¹⁷ A dichotomous outcome is needed for this analysis, so a median-split method (i.e., determining the median overall opinion score at 3 months) identified a “cutoff” POSAS score for “optimal” and “suboptimal” scars.¹⁸

Two additional exploratory analyses were performed to assess individual POSAS prediction indicators

- (1) One analysis investigated if there was a significant ($p < 0.05$) relationship between an individual POSAS item scored at 1 week versus 3 months (e.g., does vascularity at 1 week correlate with vascularity at 3 months?). A weak positive correlation was defined as Pearson’s correlation coefficient $r < 0.4$, a moderate correlation was defined as $r = 0.4–0.59$, and a strong correlation was defined as $r > 0.6$.¹⁹
- (2) In addition, we sought to identify whether individual scar characteristics at 1 week could be used to predict future scar overall appearance. A multivariable regression was used with individual POSAS items from the 1-week visit as the predictors and the 3-month overall opinion score as the outcome (e.g., does vascularity at 1 week predict overall opinion score at 3 months?).

Results

Study population

Clinical photographs for the scars of 108 patients at 1 week and 3 months postoperatively were evaluated. No patients were excluded for postsurgical interventions. The mean patient age was 63 years (SD = 13.7). Patient and scar characteristics are shown in Table 1.

Table 1. Patient demographics and scar characteristics, $n = 108$

Patient demographic	n (%)
Gender	
Male	45 (41.7)
Female	63 (58.3)
Average age	63.0 years \pm 13.7 ^a
Race	
Caucasian	108 (100)
Location within facial subunits	
Periorbital	15 (13.3)
Forehead/temple	31 (27.4)
Cheek	19 (16.8)
Nose	28 (25.9)
Perioral	15 (13.9)
Reconstruction procedure	
Linear	34 (30.1)
Local flap	44 (38.9)
Staged interpolation flap	16 (14.2)
Skin graft	12 (10.6)

^aValue is listed as mean \pm SD. SD, standard deviation.

Table 2. Overall opinion and total Patient and Observer Scar Assessment Scale scores by anatomic location and reconstruction type

Characteristic	Overall opinion item 10 (worst) 1 (best)			Total score 50 (worst) 5 (best)		
	1 week, mean (SD)	3 months, mean (SD)	Percentage improvement (%)	1 week, mean (SD)	3 months, mean (SD)	Percentage improvement (%)
Location of scar						
Periorbital ^a	4.0 (0.9)	2.7 (1.4)	34.6	20.7 (4.8)	14.6 (6.7)	31.3
Forehead/temple ^a	5.1 (1.1)	3.3 (1.1)	34.0	25.6 (5.7)	17.8 (5.7)	29.9
Cheek ^a	5.1 (1.1)	3.2 (1.1)	33.7	26.0 (5.4)	17.1 (5.2)	31.4
Nose ^a	5.4 (1.2)	2.8 (1.0)	48.6	27.7 (5.2)	14.7 (4.1)	47.0
Perioral ^a	5.4 (0.9)	3.3 (1.4)	39.7	28.0 (4.5)	16.5 (6.5)	41.1
Reconstruction procedure						
Linear ^a	4.5 (1.1)	2.7 (1.0)	38.6	23.4 (5.4)	14.9 (5.1)	35.4
Local flap ^a	5.1 (1.2)	2.9 (1.0)	42.7	26.2 (5.7)	15.3 (4.6)	20.9
Staged Interpolation flap ^a	5.5 (1.0)	3.6 (1.0)	35.4	28.0 (5.6)	18.4 (4.8)	32.3
Skin graft ^a	5.6 (0.7)	4.0 (1.7)	28.6	28.5 (3.9)	20.7 (7.9)	28.2
Average score	5.1 (0.1)	3.1 (0.1)	38.6	26.0 (5.7)	16.3 (5.6)	36.3

p-Values for all paired *t*-tests and paired Wilcoxon signed-rank test comparing scores at 1 week versus 3 month were <0.01.

^aValues are listed as mean (SD).

Scar maturation

Paired *t*-test and paired Wilcoxon signed-rank test revealed consistent results. Total POSAS score and overall opinion of scar appearance significantly improved from 1 week to 3 months postoperatively (*p*<0.001). Table 2 shows the averages for the total POSAS scores and physicians’ overall opinion for the 1-week versus 3-month postoperative photos. Total POSAS score improved by 36.3% and overall opinion improved by 38.6%. Table 3 demonstrates the percentage improvement for each POSAS item. POSAS scores for each individual scar characteristic also improved significantly from 1 week to 3 months (*p*<0.001). Surface area improved the least (23.1%), whereas vascularity improved the most (38.5%).

Scar maturation by anatomic location. Both ANOVA and the Kruskal–Wallis tests revealed consistent results. One-week total POSAS scores differed by anatomic location (*p*<0.05). Although our study was not adequately

powered to perform a post hoc analysis, periorbital scars demonstrated the best total POSAS score 1-week post-MMS (Fig. 2A). A significant difference was not observed in 3-month postoperative scar appearance when comparing anatomic facial subunits. POSAS scores significantly improved from 1 week to 3 months postoperatively in all five facial subunits (*p*<0.001). Nasal scars demonstrated the greatest absolute and relative improvement (46.9%) (Fig. 2A).

Scar maturation by reconstructive type. Total POSAS scores differed by type of reconstruction at both 1 week and 3 months postoperatively. Linear closures had the most favorable POSAS scores, whereas skin grafts had the worst POSAS score. Local flaps demonstrated the greatest absolute and relative improvement in total POSAS scores (Fig. 2B).

Ability of 1-week scar appearance to predict 3-month scar appearance

ROC Analysis: A cutoff score of 3.0 for 3-month physician overall opinion scores was determined by the median-split method to represent “optimal” (<3) and “suboptimal” (≥3) scars. Overall opinion score for 1-week postoperative scar appearance correlated with overall opinion scar for 3-month postoperative scar appearance (AUC=0.7732). Figure 3 displays the model curve.

Scar characteristics from 1 week to 3 months: Both total POSAS score and overall opinion scores for 1-week postoperative scars moderately correlated with their respective scores at 3 months. Scores for individual POSAS items at 1 week correlated with scores of the same POSAS item for the 3-month postoperative scars

Table 3. Improvement in Patient and Observer Scar Assessment Scale scores from 1 week to 3 months

POSAS item	1 week	3 months	Percentage improvement (%)
Vascularity	4.7	2.9	38.5
Pigmentation	3.8	2.7	29.2
Thickness	3.9	2.6	32.5
Relief	4.2	2.8	33.3
Surface area	4.2	3.2	23.1
Total score	25.9	16.2	36.3
Overall opinion	5.1	3.1	38.6

p-Values for all paired *t*-tests comparing scores at 1 week versus 3 months were <0.001.

POSAS, Patient and Observer Scar Assessment Scale.

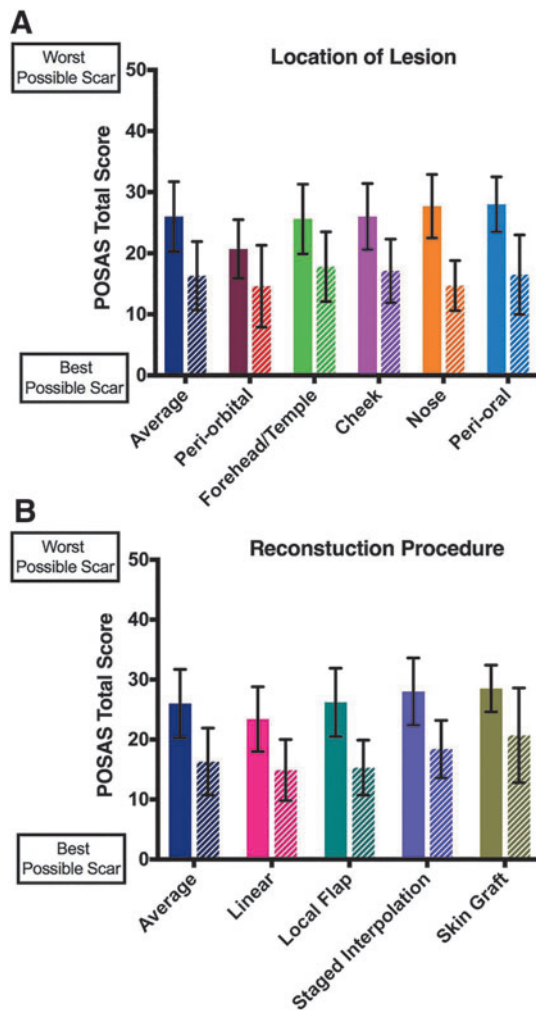


FIG. 2. Total POSAS score from 1 week to 3 months for each anatomic location (A) and reconstruction procedure (B). The first bar represents total score at 1 week and the second bar represents total score at 3 months. Periorbital scars had the best scar appearance at 1 week and 3 months, but this was only statistically significant at 1 week. Skin graft scars had the worst scar appearance at 1 week and 3 months. All improvements from 1 week to 3 months were statistically significant ($p < 0.05$). Nasal scars and scars repaired with a local flap showed the greatest absolute improvements in total POSAS score.

($p < 0.05$). Only scar surface area had a strong correlation ($r = 0.63$), such that suboptimal surface area 1-week post-MMS strongly correlated with suboptimal surface area at 3 months. Comparatively, vascularity had a weak correlation ($r = 0.24$) (Appendix Table A1 shows the correlation coefficients).

Scar characteristics at 1 week as predictors of 3-month overall scar appearance: When individual POSAS items were considered, only surface area at 1-week post-MMS significantly correlated with 3-month overall scar appearance ($p < 0.001$). Therefore, if scars were noticeable at 1 week because of extensive surface area, it was predictable that the overall scar assessment would remain noticeable 3 months postoperatively.

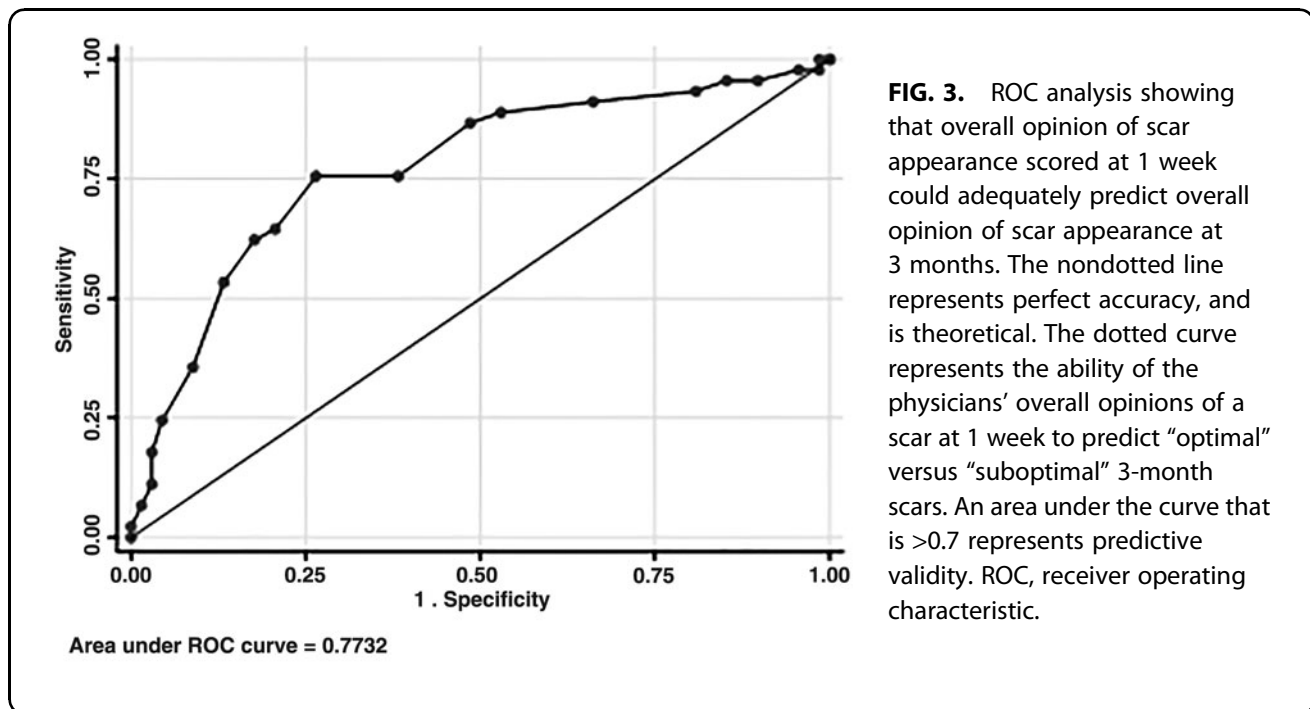
Physicians' overall opinion of scar appearance had high inter-rater reliability for scores of the 1-week postoperative photos (Cronbach's $\alpha = 0.84$) and the 3-month postoperative photos (Cronbach's $\alpha = 0.90$) follow-up visits. Similarly, the total score and nearly all items of the POSAS had high inter-rater reliability (Appendix Table A2).

Discussion

Patients frequently have peak anxiety about the appearance of scars 1 week after facial surgery. This study demonstrates that surgeons' assessments of scar appearance 1 week after surgery are predictive of scar appearance at the third postoperative month. Surgeons can counsel patients 1 week after surgery to expect improvements in vascularity, pigmentation, thickness, relief, and surface area. By the third postoperative month, an overall improvement in scar appearance of nearly 40% can be expected. Scars with large surface area and reconstructions with a skin graft show the least improvement between 1 week and 3 months postoperatively. These data are useful to set patient expectations and may influence decisions about reconstructive design.

Although all scars improved in appearance between 1 week and 3 months postoperatively, scars that were more noticeable at 1 week postoperatively had worse appearance scores at 3 months postoperatively. By contrast, scars with the best appearance scores at 1 week had the best appearance scores at 3 months. These data emphasize the importance of meticulous surgical technique, delicate tissue handling, and strategic reconstruction design to minimize scar appearance as quickly as possible.^{15,16}

Certain scar characteristics are more noticeable than others and improve less with time. Increased surface area was the most noticeable scar characteristic and the least likely to improve. Surface area was the only 1-week postoperative characteristic that correlated with overall scar appearance at 3 months postoperatively. This implies that surface area has a strong effect on early scar outcome. Differences in scar surface area may explain why skin grafts (large surface area) had the worst appearance and linear closures (small surface area) had the best appearance at both time points. Following skin graft patients beyond the 3-month mark may result in more aesthetic changes because of graft maturation and contracture. In most patients, scar width stabilizes and scar color transitions to lighter



coloring by the fourth month. Scar whiteness is the predominant color by month 6 and the surface profile of the scar is stable by month 8. It is in these later months where rete ridges form and collagen fibers become thicker and denser.¹² Similar to grafts, staged interpolation flaps have increased surface area, but they were rated with less noticeable scar appearance scores, likely because of better color and contour match.²⁰

Our results align with previous reports. Linear repairs are the most common reconstruction after skin cancer excision, and they provide reproducibly inconspicuous scars.^{21,22} Cosmetic unit excision and staged repair with regional flaps frequently offer superior results to grafts.^{23,24} These data suggest that surgeons might reduce scar appearance by choosing linear repairs and flaps over grafts, when feasible, and surgeons may consider partial closure of large defects to decrease the surface area of the graft.²⁵

Scar vascularity was often noticeable at 1 week, but it was not a significant determinate of overall scar appearance 3 months after surgery. These findings are consistent with known literature that scar erythema is physiological and can take an average of 7 months to fade.¹² Patients are commonly reassured during perioperative counseling that, as inflammation subsides and buried sutures dissolve, their scars will become less red. This process is assisted by diligent standardized wound care early in the postoperative period.²⁶ Our results may guide clinicians when considering standard postsurgical scar interventions such as pulsed dye laser and intralesional triamcinolone.

Anatomic location also influenced the early assessment of scars. Although our sample size was not ade-

quately powered for a post hoc analysis, descriptive analysis revealed that periorbital scars were graded the best at the 1-week visit. Nasal and perioral scars were graded the worst. Consistent with prior studies, observers judge a midline and centofacial asymmetry more critically than asymmetries on the lateral face.²⁷ Interestingly, nasal scar assessments improved the greatest from 1 week to 3 months. Surgeons can use these findings to reassure patients that nasal scars, although distracting 1 week after surgery, heal predictably well. Three-month scar appearance did not differ significantly based on location, which may suggest that by 3 months the reconstruction procedure rather than the anatomic site more heavily impacts aesthetic scores.

Our study is limited by assessing scar appearance through photography. The POSAS was initially validated to evaluate scars in person. To account for the inability to assess tactile information, we removed pliability from the instrument. Other studies using the POSAS have evaluated scars by photograph with this methodology and the validity of POSAS used in conjunction with photography is confirmed.²⁸⁻³⁰ The high inter-rater reliability for scores of the four clinicians at both time points further demonstrates the benefits of POSAS use. Additional limitations include physicians not blinded to time to accurately mimic clinical practice and not assessing scar appearance beyond 3 months after surgery. Identifying changes in scar improvements past this time point would be instructive, as wound remodeling can occur up to 1 year after surgery and may also influence how the surface area of skin grafts are perceived. Although this study examined the influences of anatomic location and

reconstruction type, our sample size was not sufficient to power a post hoc analysis. In addition, certain reconstructive procedures may be more commonly utilized for specific anatomic locations. A larger study would be required to perform a multivariable analysis to ensure reconstruction type was not a confounder to the differences detected among anatomic sites and vice versa. Our skin cancer patient cohort was exclusively Caucasian and elderly. These results may not be applicable to darker skin types and younger patients where scarring can be less predictable. Although patients with complications were not individually tracked, they were not excluded. Any patients with wound infection, dehiscence, or ischemia are likely to have unfavorable POSAS scores at 1 week and later at 3 months. Finally, this study only evaluated physician's perception of scar appearance. Further studies to identify if patient and observer opinions of scar appearance parallel that of physicians are underway.

In conclusion, these data provide new concrete evidence that facial scars reliably improve over 3 months after surgical reconstruction. Scars that begin healing well 1 week after surgery are more likely to heal with the highest aesthetic results at 3 months. There is a differential improvement among individual scar characteristics and certain anatomic locations and reconstructive procedures influence scar outcomes. These findings may improve the informed consent process before surgery, assist with reconstructive decision-making, and optimize postoperative patient counseling regarding healing expectations.

Author Disclosure Statement

No competing financial interests exist.

Funding Information

J.F.S. and J.R.E. received support from Dermatology Foundation Career Development Awards.

References

- Rhee JS, Matthews BA, Neuburg M, Logan BR, Burzynski M, Nattinger AB. Validation of a quality-of-life instrument for patients with non-melanoma skin cancer. *Arch Facial Plast Surg*. 2006;8(5):314–318.
- Pearl RL, Shao K, Shin TM, Miller CJ, Sobanko JF. Acute appearance concerns in patients undergoing Mohs surgery. *Dermatol Surg*. 2018;44(10):1349–1351.
- Zhang J, Miller CJ, O'Malley V, Etkorn JR, Shin TM, Sobanko JF. Patient quality of life fluctuates before and after Mohs micrographic surgery: a longitudinal assessment of the patient experience. *J Am Acad Dermatol*. 2018;78(6):1060–1067.
- Dey JK, Ishii LE, Boahene KDO, Byrne PJ, Ishii M. Measuring outcomes of Mohs defect reconstruction using eye-tracking technology. *JAMA Facial Plast Surg*. 2019;21(6):518–525.
- Rief W, Shedden-Mora MC, Laferton JA, et al. Preoperative optimization of patient expectations improves long-term outcome in heart surgery patients: results of the randomized controlled PSY-HEART trial. *BMC Med*. 2017;15(1):4.
- Bingel U, Wanigasekera V, Wiech K, et al. The effect of treatment expectation on drug efficacy: imaging the analgesic benefit of the opioid remifentanyl. *Sci Transl Med*. 2011;3(70):70ra14.
- Becker R, Doring C, Denecke A, Brosz M. Expectation, satisfaction and clinical outcome of patients after total knee arthroplasty. *Knee Surg Sports Traumatol Arthrosc*. 2011;19(9):1433–1441.
- Bourne RB, Chesworth BM, Davis AM, Mahomed NN, Charron KD. Patient satisfaction after total knee arthroplasty: who is satisfied and who is not? *Clin Orthop Relat Res*. 2010;468(1):57–63.
- Hamilton DF, Lane JV, Gaston P, et al. What determines patient satisfaction with surgery? A prospective cohort study of 4709 patients following total joint replacement. *BMJ Open*. 2013;3(4):e002525.
- McWilliams AB, Douglas SL, Redmond AC, et al. Litigation after hip and knee replacement in the National Health Service. *Bone Joint J*. 2013;95-B(1):122–126.
- Fix WC, Miller CJ, Etkorn JR, Shin TS, Howe N, Sobanko JF. Comparison of accuracy of patient and physician scar length estimates before Mohs micrographic surgery for facial skin cancers. *JAMA Netw Open*. 2020;3(3):e200725.
- Bond JS, Duncan JA, Sattar A, et al. Maturation of the human scar: an observational study. *Plast Reconstr Surg*. 2008;121(5):1650–1658.
- Draaijers LJ, Tempelman FR, Botman YA, et al. The patient and observer scar assessment scale: a reliable and feasible tool for scar evaluation. *Plast Reconstr Surg*. 2004;113(7):1960–1965; discussion 1966–1967.
- van de Kar AL, Corion LU, Smeulders MJ, Draaijers LJ, van der Horst CM, van Zuijlen PP. Reliable and feasible evaluation of linear scars by the Patient and Observer Scar Assessment Scale. *Plast Reconstr Surg*. 2005;116(2):514–522.
- Miller CJ, Antunes MB, Sobanko JF. Surgical technique for optimal outcomes: Part I. Cutting tissue: Incising, excising, and undermining. *J Am Acad Dermatol*. 2015;72(3):377–387.
- Miller CJ, Antunes MB, Sobanko JF. Surgical technique for optimal outcomes: Part II. Repairing tissue: Suturing. *J Am Acad Dermatol*. 2015;72(3):389–402.
- Mason SJ, Graham NE. Areas beneath the relative operating characteristics (ROC) and relative operating levels (ROL) curves: statistical significance and interpretation. *Q J R Meteorol Soc*. 2002;128:2145–2166.
- Goei H, van der Vlies CH, Tuinebreijer WE, van Zuijlen PPM, Middelkoop E, van Baar ME. Predictive validity of short term scar quality on final burn scar outcome using the Patient and Observer Scar Assessment Scale in patients with minor to moderate burn severity. *Burns*. 2017;43(4):715–723.
- Evans JDS. *Straightforward Statistics for the Behavioral Sciences*. Pacific Grove, Calif: Brooks/Cole Publishing; 1996.
- Burget GC, Menick FJ. The subunit principle in nasal reconstruction. *Plast Reconstr Surg*. 1985;76(2):239–247.
- Soliman S, Hatef DA, Hollier LH, Jr., Thornton JF. The rationale for direct linear closure of facial Mohs' defects. *Plast Reconstr Surg*. 2011;127(1):142–149.
- Campbell RM, Perlis CS, Malik MK, Dufresne RG, Jr. Characteristics of Mohs practices in the United States: a recall survey of ACMS surgeons. *Dermatol Surg*. 2007;33(12):1413–1418; discussion 1418.
- Larrabee YC, Phillips DJ, Sclafani AP. Trends in nasal subunit reconstruction by facial plastic and reconstructive surgeons. *Facial Plast Surg*. 2017;33(1):17–19.
- Menick FJ. Principles and planning in nasal and facial reconstruction: making a normal face. *Plast Reconstr Surg*. 2016;137(6):1033e–1047e.
- Winslow CP, Hansen J, Mackenzie D, Cohen JJ, Wax MK. Pursestring closure of radial forearm fasciocutaneous donor sites. *Laryngoscope*. 2000;110(11):1815–1818.
- Chen MA, Davidson TM. Scar management: prevention and treatment strategies. *Curr Opin Otolaryngol Head Neck Surg*. 2005;13(4):242–247.
- Springer IN, Wannicke B, Warnke PH, et al. Facial attractiveness: visual impact of symmetry increases significantly towards the midline. *Ann Plast Surg*. 2007;59(2):156–162.
- Shao K, Parker C, Taylor L, Mitra N, Sobanko JF. Reliability of the patient and observer scar assessment scale (POSAS) when used with post-surgical scar photographs. *Dermatol Surg*. 2018;44(12):1650–1652.
- Buelens S, Van Hove AS, Ongenaes K, et al. Fractional carbon dioxide laser of recent surgical scars in the head and neck region: a split-scar, evaluator-blinded study. *Dermatol Surg*. 2017;43(Suppl. 1):S75–S84.
- Lindeboom JA, Lindeboom R, Bruijnesteijn van Coppenraet ES, Kuijper EJ, Tuk J, Prins JM. Esthetic outcome of surgical excision versus antibiotic therapy for nontuberculous mycobacterial cervicofacial lymphadenitis in children. *Pediatr Infect Dis J*. 2009;28(11):1028–1030.

(Appendix follows →)

Appendix

Appendix Table A1. Individual POSAS items at 1 week predict same POSAS items at 3 months

<i>POSAS item</i>	<i>Pearson's correlation coefficient (r)</i>
Vascularity	0.24
Pigmentation	0.36
Thickness	0.30
Relief	0.53
Surface area	0.63
Total score	0.51
Overall opinion	0.52

p-Values for all correlations were <0.05. A weak positive correlation was defined as Pearson's correlation coefficient $r < 0.4$, a moderate correlation was defined as $r = 0.4-0.59$, and a strong correlation was defined as $r > 0.6$. POSAS, Patient and Observer Scar Assessment Scale.

Appendix Table A2. Reliability of physicians' Patient and Observer Scar Assessment Scale scar appearance ratings

	<i>Cronbach's alpha</i>	<i>95% CI</i>
1 week		
Vascularity	0.87	0.82–0.91
Pigmentation	0.73	0.64–0.81
Thickness	0.56	0.41–0.68
Relief	0.74	0.65–0.81
Surface area	0.75	0.67–0.82
Total	0.84	0.79–0.88
Overall	0.84	0.78–0.88
3 months		
Vascularity	0.90	0.87–0.93
Pigmentation	0.85	0.80–0.89
Thickness	0.78	0.71–0.84
Relief	0.85	0.81–0.89
Surface area	0.84	0.79–0.89
Total	0.91	0.88–0.93
Overall	0.90	0.87–0.93

All reliability measures were statistically significant at $p < 0.001$. Comparison of accuracy of patient and physician scar length estimates before Mohs micrographic surgery for facial skin cancers. CI, confidence interval.